

# The Use of Mineral Trioxide Aggregate to Repair Iatrogenic Perforations



Arnaldo  
Castellucci, MD,  
DDS

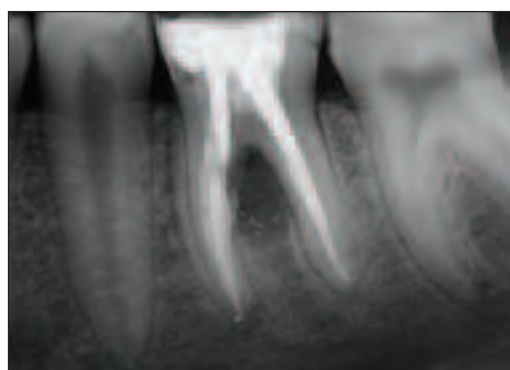
Perforations are pathologic or iatrogenic communications between the root canal system and the attachment apparatus. The clinician must be particularly concerned about avoiding perforations of the tooth during endodontic therapy, since a perforation will necessitate additional treatment. If a perforation occurs, the tooth does not necessarily require surgery, intentional re-plantation, or extraction; in fact, it can be treated successfully in a conservative manner and continue to function as it did before the perforation. Today, there is no reason to believe that the tooth will be lost prematurely because of this complication.<sup>1</sup>

An inflammatory reaction is established in the surrounding periodontium at the perforation site. This is due both to mechanical trauma and to the introduction of microbially derived substances that inevitably accompany the perforation. The perforation

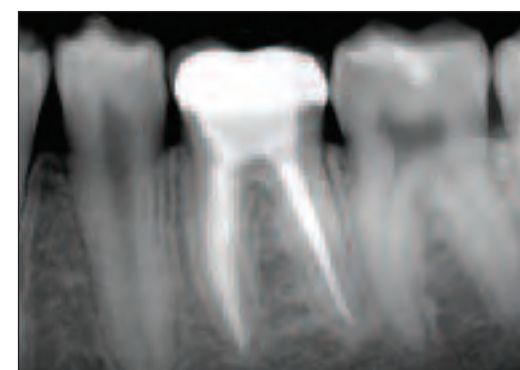
creates a portal of exit in the root canal system. Once identified, it must be sealed as quickly as possible, since periodontal involvement arising from the perforation can become irreversible with time.

Treating a perforation often requires a multidisciplinary approach in order to establish the appropriate treatment plan. The decision must be made either to extract the tooth or direct efforts toward nonsurgical retreatment, surgical correction, or both. When evaluating a perforated tooth, 4 variables should be considered: level, location, size and shape, and time.<sup>2</sup>

1. **Level.** Perforations can be considered to occur in the coronal, middle, or apical one third of the tooth. The prognosis of radicular perforations of the apical and middle third is much better than perforations of the coronal third or of the pulp chamber floor of multirooted teeth.<sup>1,3-7</sup>



**Figure 1.** Stripping of the mesial root of the mandibular left first molar, caused by the introduction of a screw post into the mesiobuccal canal. Preoperative radiograph.



**Figure 2.** The recall radiograph after 5 years demonstrates complete healing.

2. **Location.** Perforations occur circumferentially on the buccal, lingual, mesial, or distal aspects of the roots. This is an important consideration if surgical access is considered, while it is not as important in the case of nonsurgical retreatment.
3. **Size and shape.** The dimension and shape of the perforation primarily influence the establishment of a good seal. The larger the bur causing the perforation, the bigger the area to seal. Furthermore, lateral perforations are never round, but are elliptical in shape, since the bur meets the canal wall at a 45° angle. Finally, the perforating cavity has no taper, and this makes it difficult to establish a good apical seal without disturbing the surrounding periodontium.
4. **Time.** As stated, perforations create an inflammatory reaction in the adjacent tissues, and consequently a loss of attachment. Therefore, to discourage further loss of attachment and periodontal breakdown, perforations should be sealed as soon as possible, preferably during the same appointment they occur.

## PROGNOSIS

The prognosis of perforations depends on many factors, including their level (coronal, middle, or apical one third), location (buccal, palatal, mesial, or distal), size (small or large), and time interval between the perforation and obturation. Further, the prognosis depends on the material used to repair the defect, whether there is concomitant

bacterial infection, and whether there is overfilling resulting in extrusion of the repair material.

## Level

As previously noted, the literature concludes that perforations of the coronal one third and of the pulp chamber floor have a less favorable prognosis because of their vicinity to the gingival crevice.<sup>1,3-7</sup> If an adequate amount of connective tissue and bone remain coronal to the defect, there is less chance that permanent periodontal damage will occur, and healing is facilitated. For this reason, the prognosis is better in the case of a perforation of the pulpal floor in long-trunk molars. ("Trunk" is the distance between the cemento-enamel junction and the furcation).

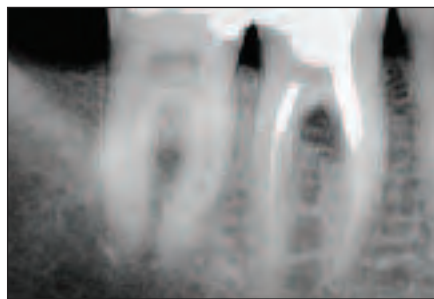
## Location

Location of the perforation is not important if the perforation can be treated nonsurgically. On the other hand, it becomes critical if surgical access is the treatment of choice. Without access, extraction of the tooth is indicated.

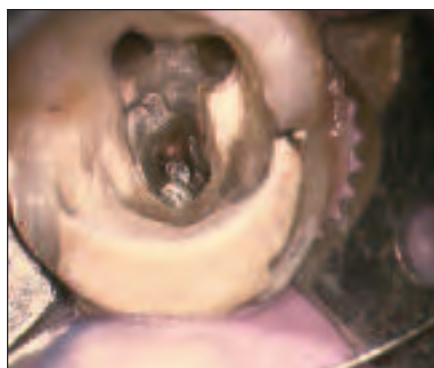## Size

As stated, a larger perforation with no taper and an ovoid opening makes treatment very challenging. It becomes more and more difficult to establish a complete seal without overfilling.

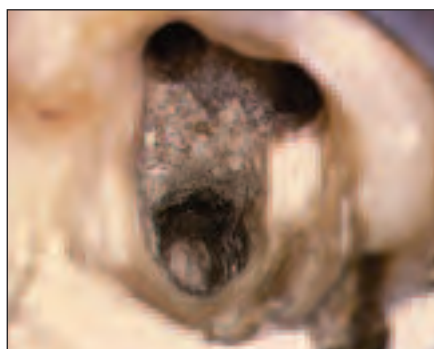
continued on page ##



**Figure 3.** Perforation of the mesial aspect of the distal root of a mandibular right first molar caused by preparation for an amalgam pin. Preoperative radiograph.



**Figure 4.** Clinical aspect of the perforation adjacent to the old amalgam.



**Figure 5.** The amalgam has been removed, and the perforation has been repaired with MTA. At the following visit the MTA is set.

### Time

Perforations result in inflammatory reactions with resultant loss of attachment. Loss of attachment can lead to the development of combined endodontic/periodontic lesions that often require a surgical procedure, and the result is a poorer prognosis. For this reason, the time interval between the perforation and treatment must be as brief as possible; in fact, it is strongly recommended that these defects be obturated immediately<sup>7</sup> during the appointment at which the perforation occurs. This helps prevent bacterial contamination and thus a lesion of the adjacent structures (ie, epithelial attachment, periodontal ligament, and bone). If still intact, these structures can function as a matrix and prevent gross overfilling at the time of obturation.

### Materials and Techniques

When repairing a perforation, visu-

alization is extremely important and is achieved by illumination and magnification. The operating microscope has dramatically improved the predictability of nonsurgical retreatment.<sup>8</sup>

Beavers, et al<sup>9</sup> have demonstrated that if the lesions heal in association with a biocompatible material, and especially in the absence of bacterial contamination, complete healing of the defect may occur following perforation of the bifurcation or with lateral perforations near the gingival sulcus, with no apical migration of the epithelial attachment.

Many different materials have been suggested to aid in the healing of a perforation, including Cavit (3M ESPE),<sup>1</sup> amalgam,<sup>3,10</sup> calcium hydroxide,<sup>11</sup> and gutta-percha.<sup>12</sup> Regardless of the material used, clinicians who seek to repair perforations have always had two challenges.<sup>13</sup> The first challenge is to establish hemostasis and avoid overfilling, which can be accomplished by placing a barrier that conforms to the furcal or root surface. Selected barriers should be biocompatible, absorbable, and supportive of new bone growth, and are placed nonsurgically through the access cavity into a 3-walled osseous defect. The internal matrix provides a barrier to control the placement of a restorative material; the barriers that are currently employed are CollaCote (Integra LifeSciences), freeze-dried bone, tricalcium phosphate, and calcium phosphate.

The second challenge to successfully repair a perforation is to select a restorative material that is easy to use, seals well, is not resorbable, is aesthetically pleasing, and is biocompatible and supports new tissue formation. The materials commonly employed to repair perforations include amalgam (decreasing in popularity), SuperEBA resin cement (Harry J. Bosworth), composite bonded material, and mineral trioxide aggregate or MTA (ProRoot MTA [DENTSPLY Tulsa Dental]).

Currently, all of the restorative materials used, except MTA, require a dry field to ensure a proper seal. Barrier material must be selected that produces a dry preparation, contains the placement of the restorative material, and prevents overfilling. The use of MTA does not require barrier material.

### PERFORATION REPAIR WITH MTA

The prognosis for a perforation has improved with the use of the operating microscope<sup>14</sup> and with the availability of MTA to seal the defects.<sup>15</sup> MTA was developed by Torabinejad and colleagues.<sup>16</sup> It is an endodontic

cement that is extremely biocompatible, hydrophilic, and capable of stimulating the healing processes and osteogenesis.<sup>17,18</sup> MTA is a powder that consists of fine trioxides and other hydrophilic particles that set in the presence of moisture. Hydration of the powder results in a colloidal gel that solidifies to a hard structure in about 4 hours. This cement is different from all other materials used because of its biocompatibility, its antibacterial activity, its marginal adaptation and sealing properties, and of primary importance because it is hydrophilic and therefore resistant to moisture.

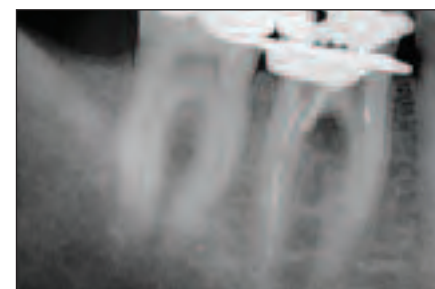
Concerning biocompatibility,<sup>19,20</sup> Koh, et al<sup>21,22</sup> and Pitt Ford, et al<sup>23</sup> demonstrated that MTA was not cytotoxic for fibroblasts or osteoblasts, and promoted the formation of dentin bridges when used in direct pulp capping.<sup>24</sup> Other studies<sup>25,26-29</sup> demonstrated the formation of cementum, periodontal ligament, and bone adjacent to MTA when used to seal perforations and as a retrofilling material in surgical endodontic procedures.<sup>30</sup>

Concerning antibacterial activity,<sup>31,32</sup> Torabinejad, et al<sup>33</sup> have demonstrated that MTA is superior to amalgam, zinc-oxide eugenol cement, and SuperEBA. Nonetheless, its spectrum of activity is limited, and if a bacterial contamination is suspected, it is advisable to use calcium hydroxide before MTA.<sup>33</sup> Marginal adaptation and sealing properties of MTA are far superior to those of amalgam, IRM, and SuperEBA.<sup>27,10,34-39</sup> [Author: who manufactures IRM?]

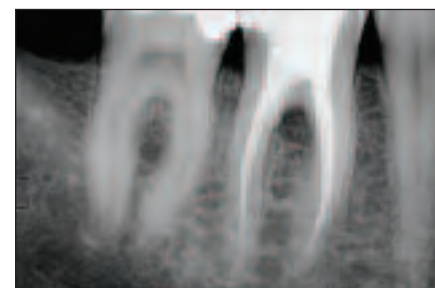
As noted, the characteristic that distinguishes MTA from all the other materials used to repair iatrogenic perforations is that it is hydrophilic. Materials used to repair perforations, seal the retro-preparation in surgical endodontics, close open apices, or protect the pulp in direct pulp cappings are inevitably in contact with blood and other tissue fluids. MTA is the only material that is not affected by moisture or blood contamination.<sup>28</sup> On the other hand, MTA sets only in contact with moisture. Due to the above-mentioned characteristics and primarily because it is hydrophilic, MTA can be considered the ideal material to seal perforations<sup>40,41-57</sup> (Figures 1 and 2).

The following is the operative sequence to treat a perforation of the root or of the floor of the pulp chamber:

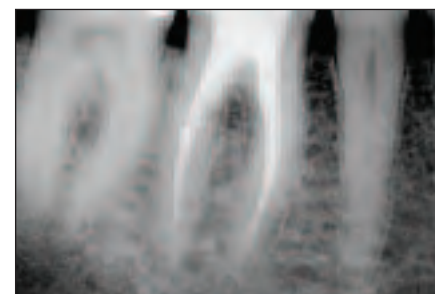
At the patient's first visit, (1) isolate the operative field with rubber dam, (2) clean the perforation site; in case of bacterial contamination,



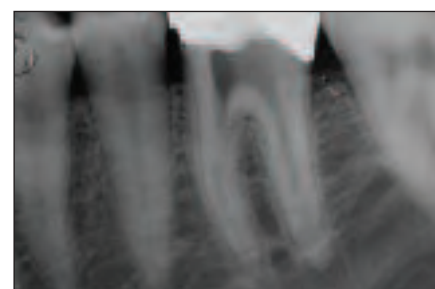
**Figure 6.** The radiograph shows the MTA in place.



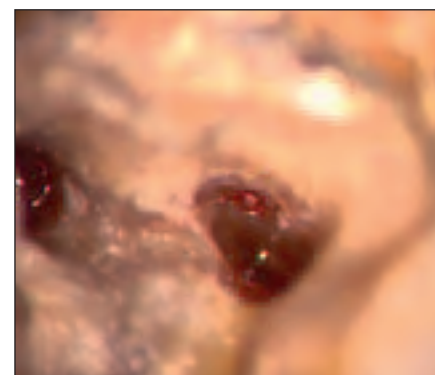
**Figure 7.** Postoperative radiograph.



**Figure 8.** A 3-year postoperative radiograph.



**Figure 9.** In the attempt to find the mesiobuccal canal, a perforation was made in the floor of the pulp chamber. Preoperative radiograph.

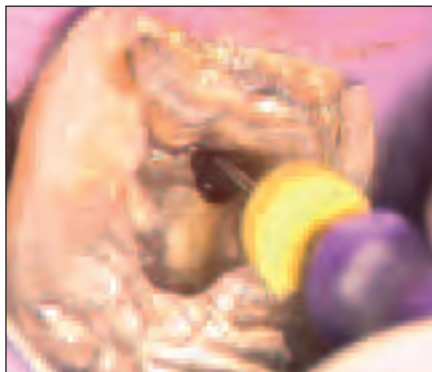

**Figure 10.** Clinical aspect of the access cavity. The red tissue on the left is the pulp tissue in the lingual canal. On the mesial aspect of the perforation the orifice of the buccal canal is visible.

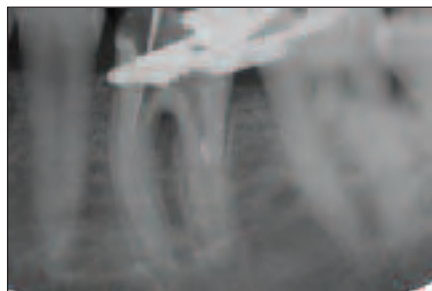
medicate with calcium hydroxide for one week, (3) apply a 2- to 3-mm-thick layer of MTA; radiograph to

Xxxx...

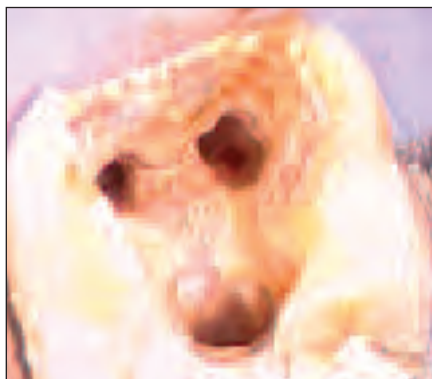continued from page



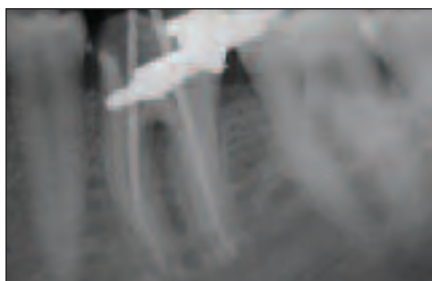
**Figure 11.** A No. 10 K-File in the original mesiobuccal canal.



**Figure 12.** Working length of the mesiobuccal canal.



**Figure 13.** After cleaning and shaping, the perforation is seen as the small opening about 7 mm below the canal orifice.

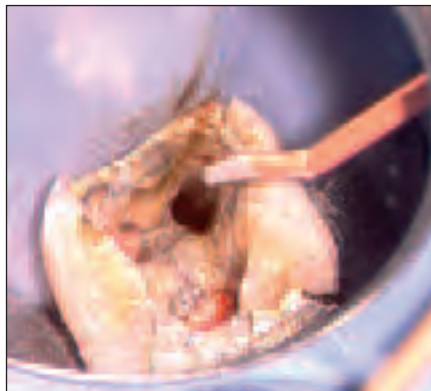


**Figure 14.** Fitting the gutta-percha cones.

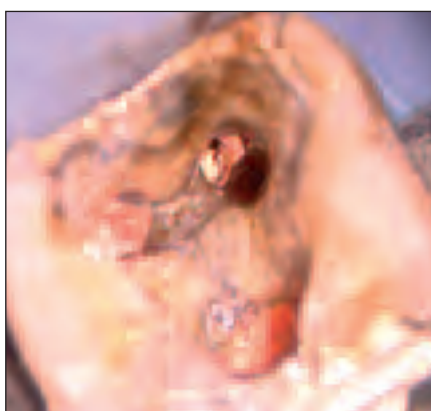verify the correct positioning of the material, (4) apply a small wet cotton pellet in contact with MTA, and (5) place temporary cement.

At the second visit (after 24 hours), remove the temporary cement to check if the MTA has set and then complete therapy.

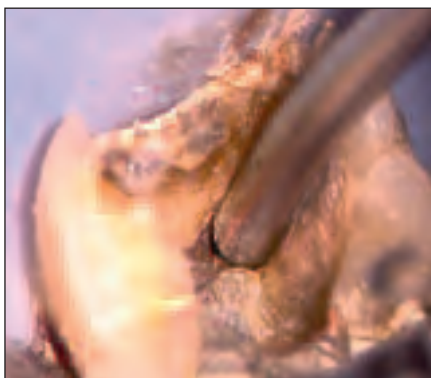
As far as the operative sequence is concerned, it is important to differentiate between a perforation that has the configuration of a cavity with 4 walls having no association with the root canal space (eg, the



**Figure 15.** The gutta-percha cone of the mesiobuccal canal has been partially pre-sectioned apical to the perforation, and is bent and coated with sealer before being introduced in the canal.



**Figure 16.** Because of the partial cut, the gutta-percha point is separated in 2 fragments: one apical, which remains in the canal apically to the perforation, and one coronally, which is removed. The canal has been obturated apical to the perforation.



**Figure 17.** Positioning the MTA with a Dovgan carrier.

perforation of the pulp chamber floor in a molar), and one that is a strip perforation inside the canal space. If the perforation is in the floor of the pulp chamber and therefore is a cavity completely independent of the canal orifices, the situation is different from a perforation that is in the middle third of a root and is caused by stripping due to excessive enlargement of the root canal. In the latter case, the perforation is not independent from the root canal but is inside the root canal (in a root canal wall). It is not a cavity with 4 walls, but is rather a thinning of the root.

In the first instance, it is advisable to seal the perforation before obturating the root canals (Figures 3

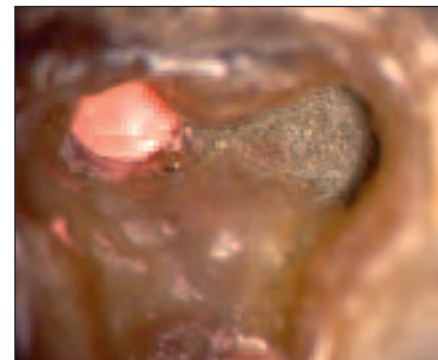
to 8). This approach is easier and saves time. Since one consideration for prognosis is the time interval between perforation and treatment, the longer treatment is delayed, the more likely the perforation site will be contaminated, with resultant periodontal involvement. After positioning small amounts of gutta-percha at the orifices of the canals using the **Obtura III (Obtura Spartan)**, or in a retreatment case before removing the previous obturating material to prevent blockage of the canals, MTA is used to completely fill the perforation. Once the complete set of the material is verified at the second visit, the cleaning, shaping, and obturation of the root canal system is completed in the standard fashion.

In the case of a strip perforation due to a thinning of the root dentinal wall, it is extremely difficult to repair the perforation site with MTA before obturating the root canal without blocking the canal itself with MTA. Therefore, it is advisable to obturate the canal space apical to the perforation first, and then to repair the perforation using MTA to seal the perforation site and fill the entire coronal portion of the root canal, to the orifice (Figures 9 to 20). In order to do this, it is necessary to measure the level of the perforation using the operating microscope and then to partially cut or score the prefitted gutta-percha cone just apical to that level. Once it is introduced into the root canal, the gutta-percha cone is digitally rotated, separating it into 2 pieces: the coronal fragment pulls away, leaving the apical fragment in the canal, which is just apical to the perforation. After compaction of the apical gutta-percha cone, the canal is filled with MTA to the orifice, sealing the perforation site.

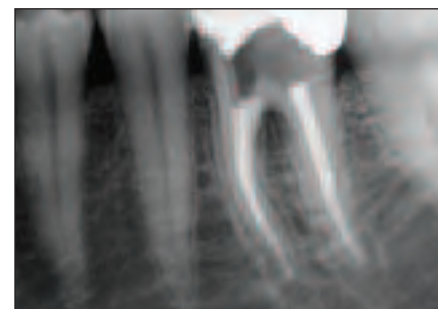
#### CRITERIA FOR DETERMINING SUCCESS

To achieve success following treatment of a perforation, the treated tooth must meet the following requirements:<sup>58</sup>

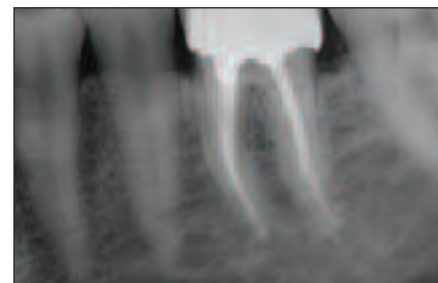
- absence of symptoms, such as spontaneous pain, or pain on palpation or percussion
- absence of excessive mobility
- absence of a communication between the perforation and the gingival crevice
- absence of a fistula
- the tooth must be functional
- absence of radiographic signs of demineralization of the bone adjacent to the perforation
- thickness of the periodontal ligament adjacent to the obturating material should be no more than double the thickness of the sur-



**Figure 18.** The canal has been filled with MTA to the orifice.



**Figure 19.** Postoperative radiograph.



**Figure 20.** A 2-year postoperative radiograph.

rounding ligament.

If only one of these criteria cannot be met, therapy cannot be considered as a success.

#### CONCLUSION

Perforations represent pathologic or iatrogenic communications between the root canal system and the periodontal attachment apparatus. Treating a perforation may often require a multidisciplinary approach in order to establish an appropriate treatment plan, and the clinicians must decide whether to extract the tooth or treat it with a nonsurgical and/or surgical approach.

The prognosis of perforated teeth is better today than it was in the past, and this is due to the improved vision provided by the operating microscope as well as the use of bio-compatible materials such as MTA. With this approach, perforations can be more predictably repaired without surgery, thus reducing the need for invasive and more costly procedures. ♦

#### References

1. Harris WE. A simplified method of treatment for endodontic perforations. *J Endod.* 1976;2:126-134.
2. Ruddle CJ. Micro-endodontic nonsurgical retreatment. *Dent Clin North Am.* 1997;41:429-454.

3. ElDeeb ME, ElDeeb M, Tabibi A, et al. An evaluation of the use of amalgam, Cavit, and calcium hydroxide in the repair of furcation perforations. *J Endod.* 1982;8:459-466.
4. Himel VT, Brady J Jr, Weir J Jr. Evaluation of repair of mechanical perforations of the pulp chamber floor using biodegradable tricalcium phosphate or calcium hydroxide. *J Endod.* 1985;11:161-165.
5. Jew RC, Weine FS, Keene JJ Jr, et al. A histologic evaluation of periodontal tissues adjacent to root perforations filled with Cavit. *Oral Surg Oral Med Oral Pathol.* 1982;54:124.
6. Martin LR, Gilbert B, Dickerson AW II. Management of endodontic perforations. *Oral Surg.* 1982;54:668-677.
7. Seltzer S, Sinai I, August D. Periodontal effects of root perforations before and during endodontic procedures. *J Dent Res.* 1970;49:332-339.
8. Kim S. Principles of endodontic microsurgery. *Dent Clin North Am.* 1997;41:481-497.
9. Beavers RA, Bergenholtz G, Cox CF. Periodontal wound healing following intentional root perforations in permanent teeth of Macaca mulatta. *Int Endod J.* 1986;19:36-44.
10. Benenati FW, Roane JB, Biggs JT, et al. Recall evaluation of iatrogenic root perforations repaired with amalgam and gutta-percha. *J Endod.* 1986;12:161-166.
11. Frank AL, Weine FS. Nonsurgical therapy for the perforative defect of internal resorption. *J Am Dent Assoc.* 1973;87:863-868.
12. Lantz B, Persson PA. Periodontal tissue reactions after surgical treatment of root perforations in dogs' teeth: a histologic study. *Odontol Revy.* 1970;21:51-62.
13. Ruddle CJ. Retreatment of root canal systems. *J Calif Dent Assoc.* 1997;25:11-?. **[I could not find this. Author, please verify if the following article is the one you intended to cite: Ruddle CJ. Nonsurgical endodontic retreatment. J Calif Dent Assoc. 1997;25:769-786.]**
14. Ruddle CJ. Endodontic perforation repair: using the surgical operating microscope. *Dent Today.* 1994;13:48-53.
15. Cantatore G, Castellucci A, Dell'agnola A, et al. Applicazioni cliniche dell'MTA. *G Ital Endod.* 2002;16:29-34.
16. Torabinejad M, Hong CU, McDonald F, et al. Physical and chemical properties of a new root-end filling material. *J Endod.* 1995;21:349-353.
17. Sarkar NK, Caicedo R, Rittwik P, et al. Physicochemical basis of the biologic properties of mineral trioxide aggregate. *J Endod.* 2005;31:97-100.
18. Thomson TS, Berry JE, Somerman MJ, et al. Cementoblasts maintain expression of osteocalcin in the presence of mineral trioxide aggregate. *J Endod.* 2003;29:407-412.
19. Ribeiro DA, Duarte MA, Matsumoto MA, et al. Biocompatibility in vitro tests of mineral trioxide aggregate and regular and white Portland cements. *J Endod.* 2005;31:605-607.
20. Ribeiro DA, Matsumoto MA, Duarte MA, et al. Ex vivo biocompatibility tests of regular and white forms of mineral trioxide aggregate. *Int Endod J.* 2006;39:26-30.
21. Koh ET, McDonald F, Pitt Ford TR, et al. Cellular response to Mineral Trioxide Aggregate. *J Endod.* 1998;24:543-547.
22. Koh ET, Torabinejad M, Pitt Ford TR, et al. Mineral trioxide aggregate stimulates a biological response in human osteoblasts. *J Biomed Mater Res.* 1997;37:432-439.
23. Pitt Ford TR, Torabinejad M, Abedi HR, et al. Using mineral trioxide aggregate as a pulp-capping material. *J Am Dent Assoc.* 1996;127:1491-1494.
24. Karabucak B, Li D, Lim J, et al. Vital pulp therapy with mineral trioxide aggregate. *Dent Traumatol.* 2005;21:240-243.
25. Camilleri J, Montesin FE, Papaioannou S, et al. Biocompatibility of two commercial forms of mineral trioxide aggregate. *Int Endod J.* 2004;37:699-704.
26. Holland R, de Souza V, Nery MJ, et al. Reaction of rat connective tissue to implanted dentin tubes filled with mineral trioxide aggregate or calcium hydroxide. *J Endod.* 1999;25:161-166.
27. Torabinejad M, Watson TF, Pitt Ford TR. Sealing ability of mineral trioxide aggregate when used as a root end filling material. *J Endod.* 1993;19:591-595.
28. Torabinejad M, Higa RK, McKendry DJ, et al. Dye leakage of four root end filling materials: effects of blood contamination. *J Endod.* 1994;20:159-163.
29. Torabinejad M, Pitt Ford TR, McKendry DJ, et al. Histologic assessment of mineral trioxide aggregate as root-end filling in monkeys. *J Endod.* 1997;23:225-228.
30. Baek SH, Plenk H Jr, Kim S. Periapical tissue responses and cementum regeneration with amalgam, SuperEBA, and MTA as root-end filling materials. *J Endod.* 2005;31:444-449.
31. Al-Hezaimi K, Naghshbandi J, Oglesby S, et al. Human saliva penetration of root canals obturated with two types of mineral trioxide aggregate cements. *J Endod.* 2005;31:453-.
32. Sipert CR, Hussne RP, Nishiyama CK, et al. In vitro antimicrobial activity of Fill Canal, Sealapex, Mineral Trioxide Aggregate, Portland cement and EndoRez. *Int Endod J.* 2005;38:539-543.
33. Torabinejad M, Hong CU, Pitt Ford TR, et al. Antibacterial effects of some root end filling materials. *J Endod.* 1995;21:403-406.
34. Adamo HL, Buruiana R, Schertzer L, et al. A comparison of MTA, Super-EBA, composite and amalgam as root-end filling materials using a bacterial microleakage model. *Int Endod J.* 1999;32:197-203.
35. Al-Kahtani A, Shostad S, Schifferle R, et al. In vitro evaluation of microleakage of an orthograde apical plug of mineral trioxide aggregate in permanent teeth with simulated immature apices. *J Endod.* 2005;31:117-119.
36. Bates CF, Carnes DL, del Rio CE. Longitudinal sealing ability of mineral trioxide aggregate as a root-end filling material. *J Endod.* 1996;22:575-578.
37. Fischer EJ, Arens DE, Miller CH. Bacterial leakage of mineral trioxide aggregate as compared with zinc-free amalgam, intermediate restorative material, and Super-EBA as a root-end filling material. *J Endod.* 1998;24:176-179.
38. Torabinejad M, Smith PW, Kettering JD, et al. Comparative investigation of marginal adaptation of mineral trioxide aggregate and other commonly used root-end filling materials. *J Endod.* 1995;21:295-299.
39. Wu MK, Kontakiotis EG, Wesselink PR. Long-term seal provided by some root-end filling materials. *J Endod.* 1998;24:557-560.
40. Bargholz C. Perforation repair with mineral trioxide aggregate: a modified matrix concept. *Int Endod J.* 2005;38:59-69.
41. De-Deus G, Petruccioli V, Gurgel-Filho E, et al. MTA versus Portland cement as repair material for furcal perforations: a laboratory study using a polymicrobial leakage model. *Int Endod J.* 2006;39:293-298.
42. Main C, Mirzayan N, Shabahang S, et al. Repair of root perforations using mineral trioxide aggregate: a long-term study. *J Endod.* 2004;30:80-83.
43. Yildirim T, Gencoglu N, Firat I, et al. Histologic study of furcation perforations treated with MTA or Super EBA in dogs' teeth. *Oral Surg Oral Med Oral Pathol Oral Radiol Endod.* 2005;100:120-124.
44. Lee SJ, Monsef M, Torabinejad M. Sealing ability of a mineral trioxide aggregate for repair of lateral root perforations. *J Endod.* 1993;19:541-544.
45. Pitt Ford TR, Torabinejad M, McKendry DJ, et al. Use of mineral trioxide aggregate for repair of furcal perforations. *Oral Surg Oral Med Oral Pathol Oral Radiol Endod.* 1995;79:756-762.
46. Fuss Z, Trope M. Root perforations: classification and treatment choices based on prognostic factors. *Endod Dent Traumatol.* 1996;12:255-264.
47. Nakata TT, Bae KS, Baumgartner JC. Perforation repair comparing mineral trioxide aggregate and amalgam using an anaerobic bacterial leakage model. *J Endod.* 1998;24:184-186.
48. Sluyk SR, Moon PC, Hartwell GR. Evaluation of setting properties and retention characteristics of mineral trioxide aggregate when used as a furcation perforation repair material. *J Endod.* 1998;24:768-771.
49. Weldon JK Jr, Pashley DH, Loushine RJ, et al. Sealing ability of mineral trioxide aggregate and super-EBA when used as furcation repair materials: a longitudinal study. *J Endod.* 2002;28:467-470.
50. Ferris DM, Baumgartner JC. Perforation repair comparing two types of mineral trioxide aggregate. *J Endod.* 2004;30:422-424.
51. Regan JD, Witherspoon DE, Foyle DM. Surgical repair of root and tooth perforations. *Endodontic Topics.* 2005;11:152-178.
52. Arens DE, Torabinejad M. Repair of furcal perforations with mineral trioxide aggregate: two case reports. *Oral Surg Oral Med Oral Pathol Oral Radiol Endod.* 1996;82:84-88.
53. Bryan EB, Woollard G, Mitchell WC. Nonsurgical repair of furcal perforations: a literature review. *Gen Dent.* 1999;47:274-278.
54. Holland R, Filho JA, de Souza V, et al. Mineral trioxide aggregate repair of lateral root perforations. *J Endod.* 2001;27:281-284.
55. Hamad HA, Tordik PA, McClanahan SB. Furcation perforation repair comparing gray and white MTA: a dye extraction study. *J Endod.* 2006;32:337-340.
56. Zou L, Liu J, Yin S, et al. In vitro evaluation of the sealing ability of MTA used for the repair of furcation perforations with and without the use of an internal matrix. *Oral Surg Oral Med Oral Pathol Oral Radiol Endod.* 2008;105:61-65.
57. Yildirim G, Dalci K. Treatment of lateral root perforation with mineral trioxide aggregate: a case report. *Oral Surg Oral Med Oral Pathol Oral Radiol Endod.* 2006;102:55-58.
58. Stromberg T, Hasselgren G, Bergstedt H. Endodontic treatment of traumatic root perforations in man: a clinical and roentgenological follow-up study. *Sven Tandlak Tidsskr.* 1972;65:457-466.

---

**Dr. Castellucci** graduated in medicine at the University of Florence (Italy) in 1973 and specialized in dentistry at the same university in 1977. As well as maintaining a practice limited to endodontics in Florence, he is past president of the Italian Endodontic Society, past president of the International Federation of Endodontic Associations, an active member of the European Society of Endodontology, an active member of the American Association of Endodontists, and a visiting professor of endodontics at the University of Florence Dental School. He is editor of *The Italian Journal of Endodontics* and of *The Endodontic Informer*. An international lecturer, he is the author of the text *Endodontics*, which is now available in English. He can be reached at castellucci@dada.it.

# Continuing Education

## Test No. 105.#



To submit Continuing Education answers, use the answer sheet on this page. On the answer sheet, identify the article (this one is Test 105.#), place an X in the box corresponding to the answer you believe is correct, detach the answer sheet from the magazine, and mail to Dentistry Today Department of Continuing Education.

The following 8 questions were derived from the article *The Use of Mineral Trioxide Aggregate to Repair Iatrogenic Perforations* by Arnaldo Castellucci, MD, DDS, on pages # through #.

### Learning Objectives

After reading this article, the individual will learn:

- the prognosis of iatrogenic perforations, and
- techniques and materials for treating perforations.

- Once a perforation is identified, \_\_\_\_\_.
  - it must be sealed as quickly as possible
  - it should be monitored radiographically for 3 to 6 months
  - the tooth should be immediately extracted
  - surgical intervention is the only treatment option
- Variables for evaluating a perforated tooth include \_\_\_\_\_.
  - level of the perforation
  - location of the perforation
  - size and shape of the perforation
  - all of the above
- Which of the following perforations has the worst prognosis?
  - coronal third
  - radicular
  - middle third
  - both b and c
- Location of a perforation \_\_\_\_\_.
  - is important if it can be treated nonsurgically
  - is not important if it can be treated nonsurgically
  - is not important if it is treated surgically
  - both a and c
- The following restorative material does not require a dry field to ensure proper seal of a perforation \_\_\_\_\_.
  - amalgam
  - MTA
  - SuperEBA resin cement
  - composite bonded material
- Mineral trioxide aggregate (MTA) is \_\_\_\_\_.
  - hydrophobic
  - hydrophilic
  - not biocompatible
  - not antibacterial
- Hydration of MTA powder results in a colloidal gel that solidifies to a hard structure in \_\_\_\_\_.
  - about 1 hour
  - about 2 hours
  - about 3 hours
  - about 4 hours
- The following statement is TRUE:
  - MTA is affected by moisture or blood contamination.
  - If bacterial contamination is suspected, it is advisable to use calcium hydroxide before MTA.
  - The antibacterial spectrum of activity of MTA is very broad.
  - For a strip perforation inside the root canal space, the perforation should be sealed before obturating the canals.

## Answer Sheet for Test 105.#

	A	B	C	D
1				
2				
3				
4				
5				
6				
7				
8				

Please evaluate this month's article.

Poor = 0 to Excellent = 5

Test 105.#

Course objectives were achieved. \_\_\_\_\_

Content was useful and benefited your clinical practice. \_\_\_\_\_

Review questions were clear and relevant to the editorial. \_\_\_\_\_

Illustrations and photographs were clear and relevant. \_\_\_\_\_

Written presentation was informative and concise. \_\_\_\_\_

How much time did you spend reading the article & completing the test? \_\_\_\_\_

✓ Check one of the following:

I wish to enroll. Enclosed is \$140 for a 6-month or \$240 for a 1-year enrollment payable to Dentistry Today CE Program. (Enrollment terms are consecutive months.)

I am currently enrolled in the CE program. Please process this month's exam.

I am not enrolled. Enclosed is \$20 for one test; \$40 for both.

I am using a credit card. My information is provided below.

AMEX, Visa, MC, & Discover cards are accepted. Please complete the following:

Credit Card Type \_\_\_\_\_ Name on Card \_\_\_\_\_

Credit Card # \_\_\_\_\_ Expiration Date \_\_\_\_\_

Signature \_\_\_\_\_

Columbia University College of Dental Medicine is an ADA/CERP-recognized provider, AGD-accepted national sponsor. FAGD/MAGD credit 11/2005 through 12/2009.

**September CE Test Deadline is February 28, 2009**

Complete the answer sheets and submit your answers for this issue's CE examinations. Answer at least six of the eight questions correctly to earn one CE credit per article.

Mail this completed sheet (originals only, no photocopies) and the appropriate fee to:



**Dentistry Today**  
Department of Continuing Education  
100 Passaic Avenue, Fairfield, NJ 07004

Note: There is a \$10 surcharge to process a check drawn on any bank other than a US bank. Should you have additional questions, please contact us at: (973) 882-4700.

Last Name \_\_\_\_\_ (PLEASE PRINT OR TYPE CLEARLY)

First Name \_\_\_\_\_ Title \_\_\_\_\_

Social Security Number \_\_\_\_\_

Street Address \_\_\_\_\_ Suite or Apartment Number \_\_\_\_\_

City \_\_\_\_\_ State \_\_\_\_\_ Zip Code \_\_\_\_\_

Daytime Telephone Number With Area Code \_\_\_\_\_

Fax Number With Area Code \_\_\_\_\_

E-mail Address \_\_\_\_\_

**SPECIAL** annual tuition available for 12-month (24 CE) and 6-month (12 CE) programs, or you may pay \$20 for each individual CE credit.

\* Only \$10 per credit with purchase of 1-year enrollment.

**Columbia University College of Dental Medicine provides peer review and issuance of Continuing Education credit.**