

Spatial localization in radiology: the buccal object rule

Author_ Arnaldo Castellucci, Italy

In no other branch of dentistry does radiology play such an important role as in endodontics. The discovery of X-rays by Wilhelm Conrad Roentgen on the night of November 8, 1895, had such a profound impact on the entire medical world that it has come to be considered one of the most revolutionary achievements in the history of medical science.

In the field of dentistry, endodontics is surely the branch that has benefited most from this discovery, not only because of continual technical and technological improvements,¹ but mainly because the use of X-rays has brought dentists "out of the dark," allowing them to visualize areas not accessible by other diagnostic means.

X-rays are electromagnetic radiations. They have the same nature as visible light rays; like them, X-rays travel in a straight line until they are either absorbed or deflected. In contrast to visible light, however, they are not perceptible to the eye because of their short wavelength (10⁻¹⁰ to 10⁻⁶ cm).² Differences among the various types of electromagnetic radiation depend upon their wavelength. Starting with the longest wavelengths, electromagnetic radiation includes:

- ▶ Electric waves
- ▶ Radio, television, and radar waves

- ▶ Infrared rays
- ▶ Visible light rays
- ▶ Ultraviolet rays
- ▶ X-rays
- ▶ Gamma rays

Depending on its wavelength, which is measured in Ångström units (Å), electromagnetic radiation has variable capacity to pass through solid bodies. Rays with longer wavelengths have poor penetrating power. In contrast, those with shorter wavelengths, beginning with ultraviolet light, have increasing penetrating power. The wavelength of the X-rays used in oral radiography vary from 0.8 to 0.1 Å; thus, their penetrating power is greater than that of ultraviolet rays.³

Apart from the radiation's wavelength, the penetrating power depends on the atomic mass (density) of the object penetrated. Low-density objects are almost completely penetrated, while higher-density objects are penetrated to a lesser extent. Lead does not allow X-rays to pass at all; therefore, it is an optimal protective material against the harmful effects of X-rays.

If one examines X-rays passing through an object, one finds that a portion of them have been absorbed by the object, which therefore projects a "shadow," like an opaque body struck by a beam of light.

Just as bodies of varying opacity hit by light rays throw different shadows depending on their capacity to be traversed by luminous radiation, bodies of variable density struck by X-rays throw different shadows depending on their capacity to be penetrated by these electromagnetic radiations.

Because less dense bodies (e.g., soft tissues) are traversed to a greater degree, they throw lighter shadows, while denser bodies (e.g., bone) are traversed less and draw more radiation, for which reason they throw darker shadows. One must keep in mind, however, that because the radiographic image is a negative, the shadows appear to be reversed: soft tissues appear

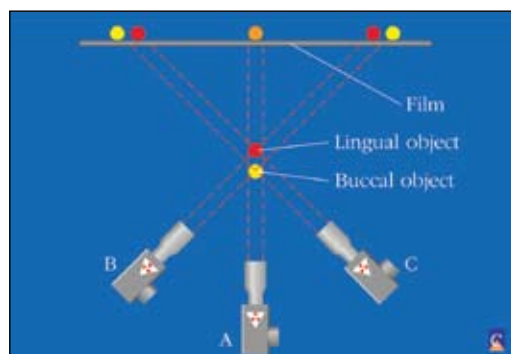


Fig. 1 _ With an orthoradial projection (A), the two objects appear superimposed. With an oblique projection (B, C), the two objects cease to be superimposed and easily become recognizable when the angulation of the X-ray machine is known: the buccal object (the one closest to the radiographic source) is displaced in the same direction as the X-rays.

AMED ad

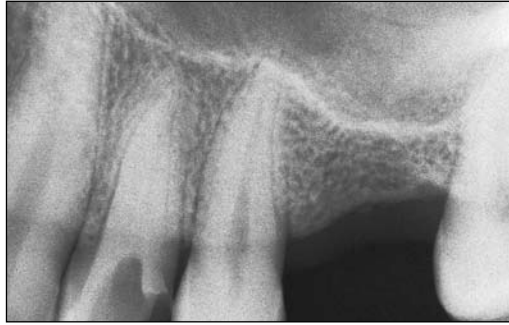

Fig. 2a With the standard projection, the roots appear superimposed.

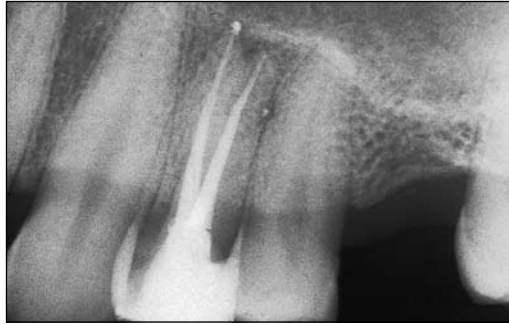

Fig. 2b Angling the X-ray machine in a mesiodistal direction, the buccal root appears close to the second premolar, while the palatal root appears close to the canine.

dark, while bone appears light.

In conclusion, the images produced by radiography represent the shadows that bodies of different densities project onto a film when placed in the X-ray's path.

Furthermore, a radiograph is a two-dimensional representation of three-dimensional structures. In other words, it is a fictitious image and never a real image⁴ with all the consequences this implies.

In practice, it is nevertheless frequently necessary to extract three-dimensional information to allow better spatial localization of certain structures with respect to others.

The most frequently used and most easily per-

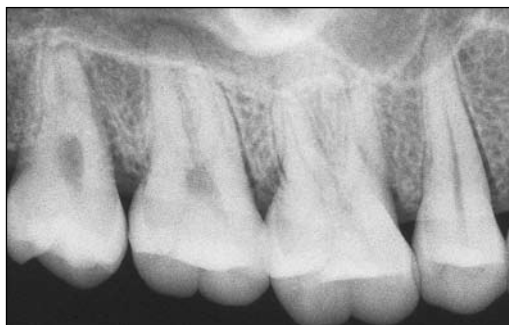

Fig. 3a This radiograph demonstrates the apices of the buccal roots of the second molar superimposed on the palatal root.

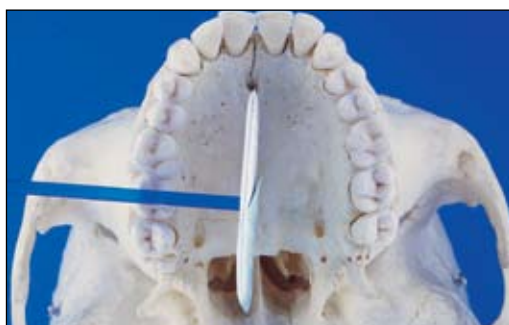

Fig. 3b Path of the X-rays in a standard projection.

formed method for obtaining such information is the "Buccal object rule," which was described by Clark⁵ in 1910 and refined and amplified by Richards in 1953⁶ and 1980.⁷ According to this rule, when a radiograph is performed at a certain angle, the object closer to the radiographic source – the buccal object – is displaced in the radiograph in the same direction as the X-ray beam. This rule, which is used to determine the relative buccal-lingual location of different structures of the oral cavity,⁸ is of fundamental importance in dentistry in general, but in endodontics in particular, where it finds numerous practical applications (Fig. 1).

The first such application is recognizing the apex of the buccal root during endodontic treatment of a first upper premolar with two roots (Figs. 2a, 2b).

To determine from radiographic examination of a first upper premolar which of the two roots is the buccal and which the palatal, it suffices to know the angle of the X-ray beam and to examine the radiograph closely. If the radiograph has been done at a slight mesiodistal angle, the X-rays have been directed from mesial to distal; therefore, the buccal root (closer to the radiographic source as compared to the palatal, which is obviously farther) will appear in the radiograph to be displaced in the same direction as the X-ray beam, that is, distally. In other words, the buccal root will appear to be closer to the root of the second premolar, while the palatal root will appear closer to the root of the canine.

If this technique is standardized so that the upper premolars are always radiographed at a slight mesiodistal angle, the buccal roots will always appear to be distal, while the palatal roots will be mesial. Obviously, if the angle of the X-ray beam was reversed in a distomesial direction, the buccal root would appear close to the canine in the radiograph, while the palatal would appear close to the second premolar.

Such displacements may not be so easily obtained in the radiograph if the tooth is unnaturally rotated around its own axis.

The same rule also applies to the upper molar region, which many endodontists consider one of the most difficult zones to treat because of the difficulty of obtaining properly oriented radiographs that show the apices of the roots that require treatment without the superimposition of nearby anatomical structures.

In the case of upper molars, especially if their roots are not wide apart, radiographs frequently demonstrate the apices of the buccal roots to be superimposed on the palatal root (Figs. 3a, 3b).

For good visualization of the distobuccal root, the X-ray tube can be angled mesiodistally. In this way, the distobuccal root (buccal object with respect to the palatal root) is displaced distally and is therefore uncovered from the superimposed shadow of the palatal root, to lie in the space mesial to the mesiobuccal root of the second molar (Figs. 4a–4c). When, once the preparation of the distobuccal canal has been

ESMD ad

Fig. 4a_ Angulation of the X-rays mesiodistally takes away the distobuccal root from the superimposition with the palatal root.

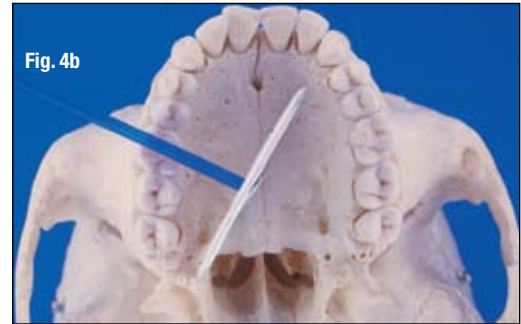
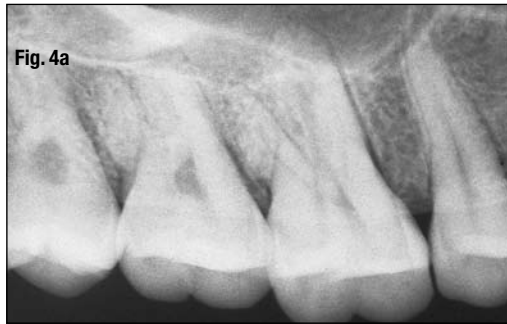
Fig. 4b_ Path of the X-rays in the mesiodistal projection.

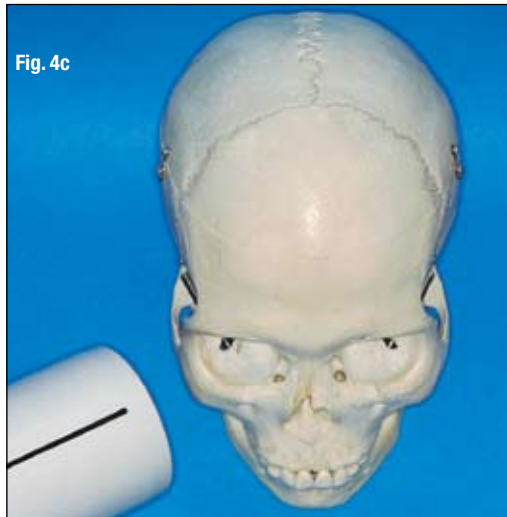


Fig. 4c_ Mesiodistal angulation.

Another anatomical structure that can complicate treatment of the molars is the zygomatic process of the maxillary bone. This structure can be superimposed on the apices of the molar under treatment, making it difficult, if not impossible, to determine the working length of the instruments. In this case also, the application of Clark's rule can be enormously helpful, as this structure is on a different plane (more buccal) with respect to the apices that we are treating.

In the case of the upper first molars, it is advisable that the shadow of this structure is displaced distally, angling the X-rays mesiodistally. This angle permits perfect visualization of the apices of the palatal root and of the distobuccal root (Figs. 6a–6d).

In the case of the upper second molars, on the other hand, it is frequently necessary to displace the shadow of the zygomatic process mesially, angling the radiographic cone distomesially.

A radiolucency that appears above the apex of a tooth is not always on the same plane as that apex, and therefore is not always strictly related to it (Fig. 7a).

A second radiograph taken with a different angulation (Fig. 7b) can reveal, for example, that that radiolucent zone is situated in a palatal position with respect to the apex of the tooth (which therefore responds normally to the vitality tests) and therefore that one is not dealing with a lesion of endodontic origin, but rather, for example, the incisive foramen.

If one were dealing with a lesion and therefore if the two structures were in contact, there would be no dis-

completed and one continues to the mesiobuccal canals, it is necessary to change the angle, because if the same angle is maintained, the mesiobuccal root appears completely superimposed on the palatal root. Therefore, this time the X-ray angle will be distomesial, so that the root is displaced mesially and in the new radiograph it appears in the space immediately distal to the second premolar (Figs. 5a, 5b).

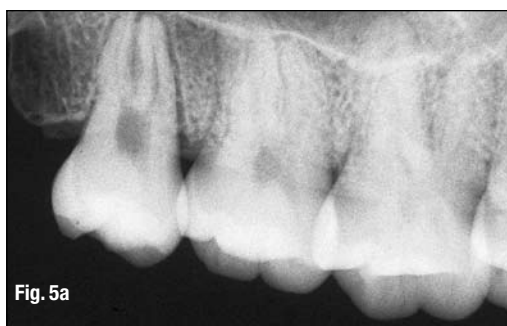

Fig. 5a_ Distomesial angulation reveals the mesiobuccal root not superimposed on the palatal root.

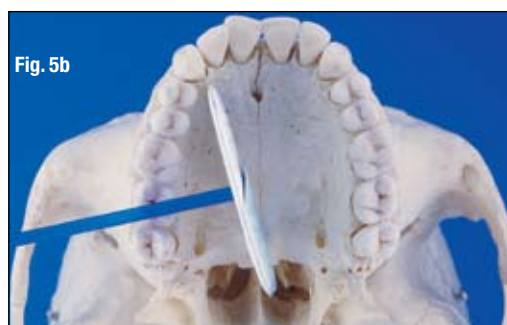

Fig. 5b_ Path of the X-rays in the distomesial projection.

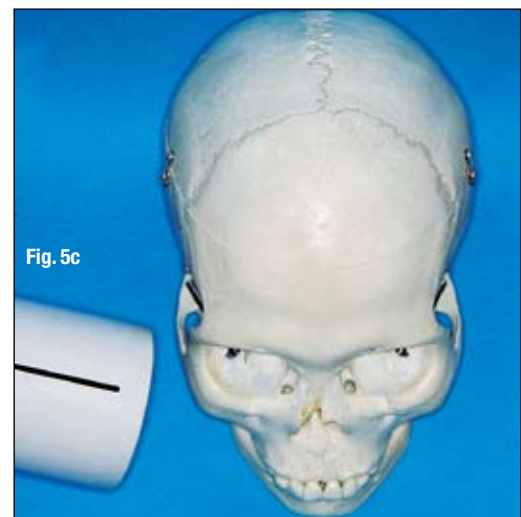

Fig. 5c_ Distomesial angulation.

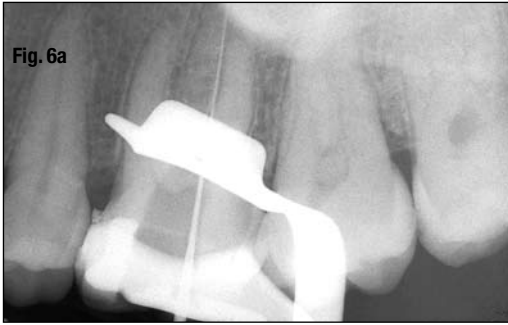

Fig. 6a

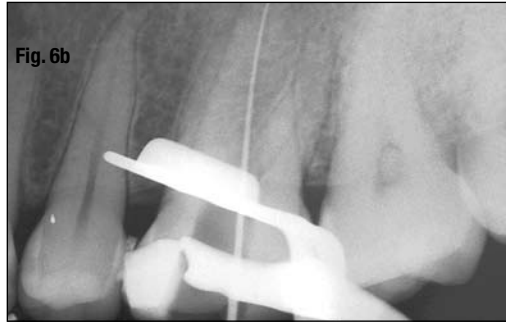


Fig. 6b

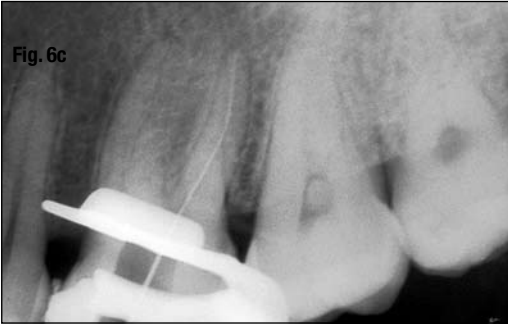

Fig. 6c

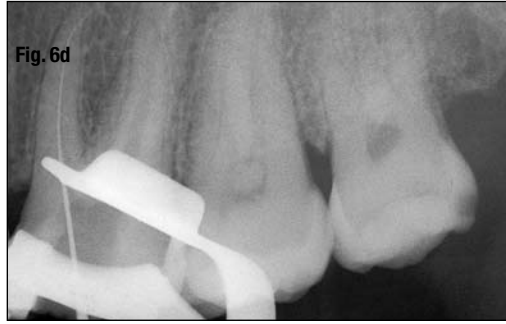

Fig. 6d

Fig. 6a Application of the buccal object rule in the upper first molar for visualization of each root. The shadow of the zygomatic process completely obscures the apex of the palatal root.

Fig. 6b The X-ray machine has been angled mesiodistally (to displace the shadow distally) and also slightly coronal-apically (to displace the same shadow more apically). Note that the shadows of the wings of the clamp are closer together consequent to the latter angulation.

Fig. 6c Keeping the preceding radiographic angulation, the working length of the distobuccal canal is checked.

Fig. 6d The X-ray machine has been angled distomesially: The palatal and distobuccal roots appear superimposed, while the mesiobuccal root is visible in its entire length.

placement of their images in the two radiographs.^{9,10}

Another clinical situation in which the application of the buccal object rule can be of use is the presence of a foreign body. A comparison of two radiographs taken at different angles can suggest the site (buccal or lingual) of the foreign body and thus the surgical approach for its removal (Figs. 8a, 8b).

Before beginning an apicectomy in the zone of the lower molars, it is obviously important to know the relationship between the apex of the roots being treated and the course of the mandibular canal. Two radiographs differing in their vertical angulation confirm that the apices of interest are in a more buccal position with respect to the course of the mandibular

canal (Figs. 9a, 9b).

A radiolucency at the apex of a lower premolar can be due to the radiographic image of the mental foramen (Figs. 10a–10c). The application of Clark's rule provides information on the spatial relationships between the two anatomical structures. If in the distomesial radiograph the radiolucency loses contact with the apex of the premolar and migrates mesially, it surely represents the mental foramen.

Furthermore, it is possible to determine whether a dental inclusion is buccal or palatal in location. This obviously allows the appropriate surgical approach.

In the case of Figs. 11a and 11b, it was ascertained by application of the buccal object rule that the curve

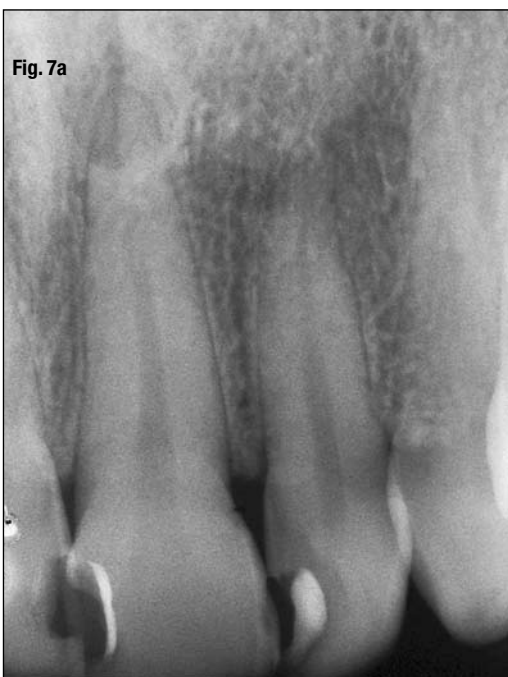

Fig. 7a

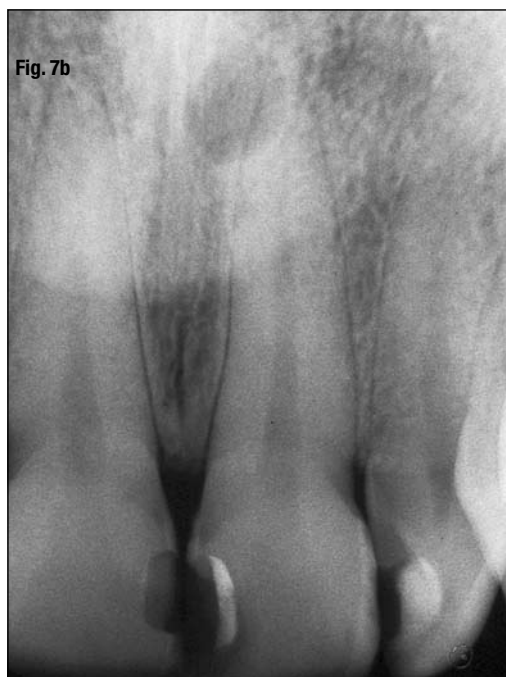

Fig. 7b

Fig. 7a The maxillary left central incisor presents a small, roundish radiolucency superimposed on the apex. Note the presence of the lamina dura, an index of health and integrity of the periodontal ligament. The tooth responds normally to all the vitality tests, hence the radiolucency cannot be interpreted as a lesion of endodontic origin.

Fig. 7b A second radiograph taken with a more pronounced mesio-distal angulation shows that the radiolucency is no longer related to the root apex, which evidently lies on a more buccal plane. The radiolucency can therefore be assumed to represent the incisor or nasopalatine foramen.

Fig. 8a_The patient claims to have been hit with shot. Therefore, the round, radiopaque image seen at the level of the apex of the distal root represents a hunting shot.

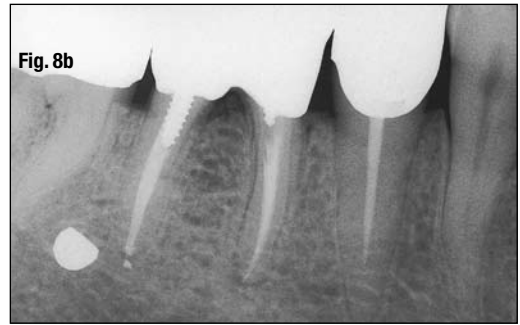
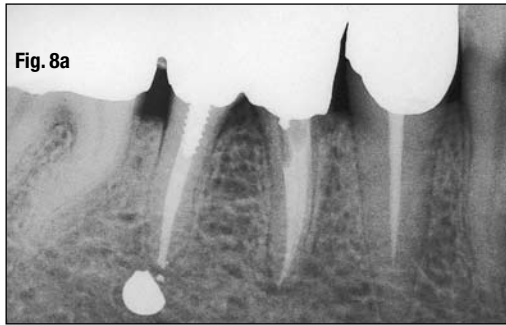


Fig. 8b_A second radiograph with a mesiodistal angulation reveals that the shot is not in contact with the root apex, but is more buccal.

Fig. 9a_A metallic wire introduced into the dry mandible in the mandibular spine demonstrates the path of the mandibular canal.

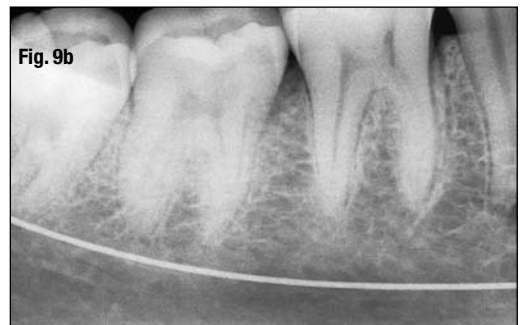
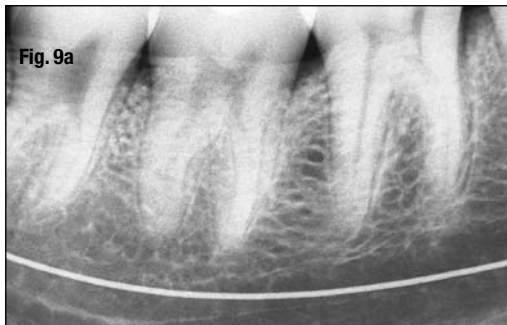
Fig. 9b_A second radiograph obtained with greater corono-apical angulation (supero-inferiorly) confirms the more lingual position of the mandibular canal with respect to the apices of the second and third molars.

Fig. 10a_The radiolucency at the apex of the lower second premolar could be diagnosed as a lesion of endodontic origin.

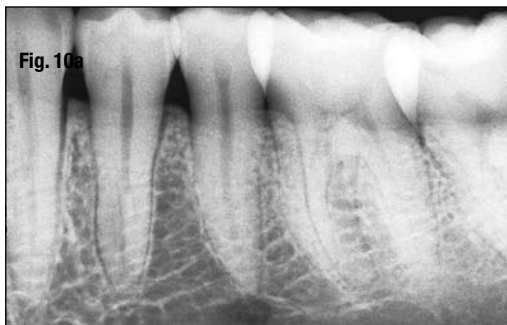

Fig. 10b_A second radiograph taken with a different angulation (disto-mesial) confirms that the radiolucency is none other than the mental foramen.

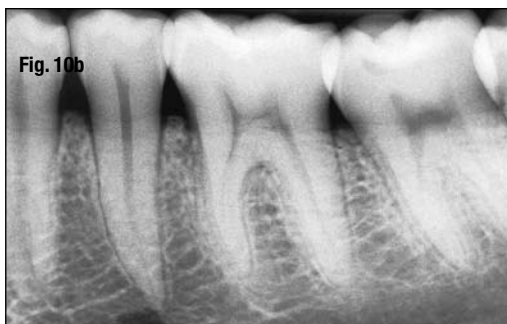
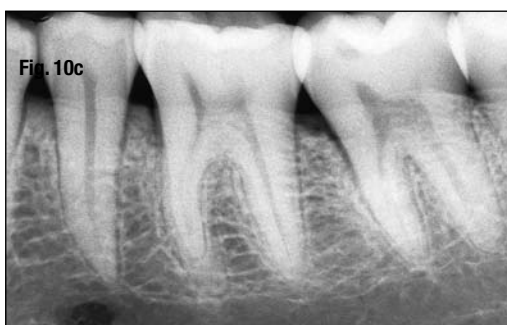
Fig. 10c_A third radiograph with increased corono-apical angulation confirms once again that the structure is more buccal with respect to the apex of the second premolar.



of the apical one third of the root of the upper right central incisor was directed in a buccal direction.

Other examples? To which root does the image of a certain canal filling correspond? Is the broken instrument present in the lingual canal or in the buccal canal? One finally found one canal in the mesial root of a lower molar: is one in the mesiobuccal or mesiolingual canal? To which cusp on the preoperative radiograph must one refer to determine the working length of the instruments? The images are superimposed: what new angle must one give to the X-ray tube? Does the root lie in the maxillary sinus or is it buccal to it? A tooth is partially hidden by one wing of the dam clamp: is it the buccal or the palatal wing? The root has an external resorption: is it on the buccal or on the palatal side of the root?

These are only some examples of the practical application of the buccal object rule, which can and must be applied each time the spatial location of two anatomical entities or structures, one buccal and the other lingual or palatal, must be determined.

References

1. Richards, A.G., Colquitt, W.N.: Reduction in dental X-ray exposures during the past 60 years. *J. Am. Dent. Assoc.* 103:713, 1981.
2. Caldirola, P., Olivieri Sangiacomo, F., Loinger, A.: *Elementi di Fisica. Volume II, Ed. III.* Ghisetti e Corvi. Milano, 1962.
3. Anderson, P.C.: *Dental Radiology.* Delmar Publishers, Albany, N.Y., 1974.
4. Pecchioni, A.: *Endodonzia. Manuale di Tecnica Operativa.* IV ed. I.C.A. Milano, 1986.

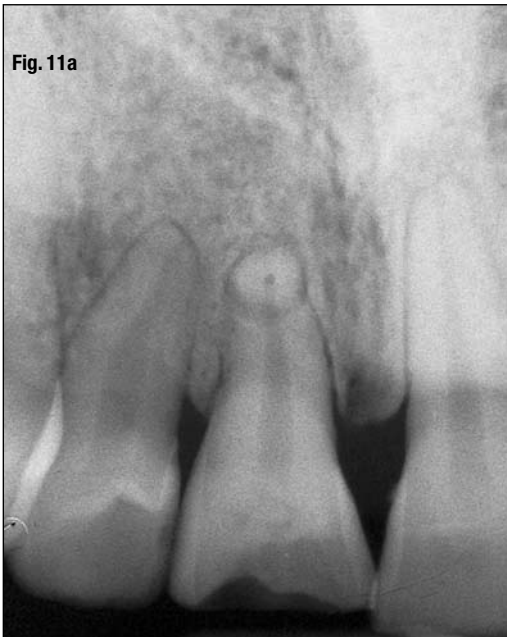

Fig. 11a

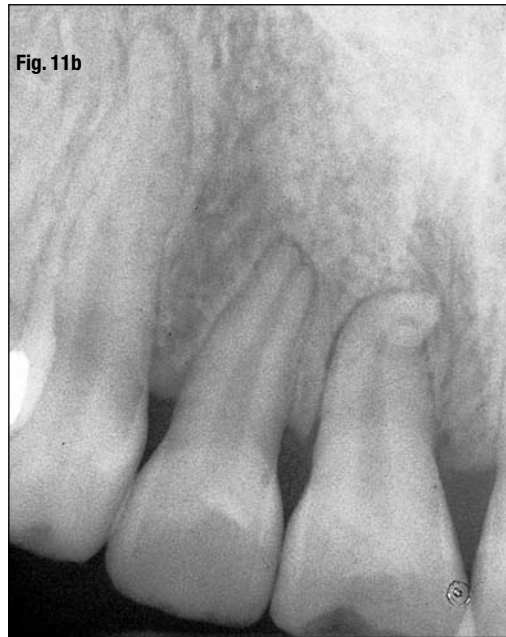

Fig. 11b

Fig. 11a_Preoperative radiograph of the upper right central incisor. The apical foramen rests on the same plane as the path of X-rays: It could be facing buccally or palatally.

Fig. 11b_A second radiograph with a distomesial angulation reveals that the curve faces buccally.

5. Clark, C.A.: A method of ascertaining the relative position of unerupted teeth by means of film radiographs. *Odontology Section, Royal Society of Medicine Transactions*. 3:87, 1910.
6. Richards, A.G.: The buccal object rule. *Tenn. State Dent. Assoc.* 33:263, 1953.
7. Richards, A.G.: The buccal object rule. *Dent. Radiogr. Photogr.* 53:37, 1980.
8. Goerig, A.C., Neaverth, E.J.: A simplified look at the buccal object rule in endodontics. *J. Endod.* 13:570, 1987.
9. Fava, L.R.G., Dummer, P.M.H.: Periapical radiographic techniques during endodontic diagnosis and treatment. *Int. Endod. J.* 30:250, 1997.
10. Richards, A.G.: La regola dell'oggetto vestibolare. *Dental Cadmos* 6:17, 1987.

_Author info


roots

Dr. Arnaldo Castellucci

Dr. Castellucci graduated in Medicine at the University of Florence in 1973 and specialized in Dentistry at the same University in 1977. From 1978 to 1980 he attended continuing education courses in endodontics at Boston



University School of Graduate Dentistry with Prof. Herbert Schilder. As well as running a practice limited to endodontics in Florence, Italy, Dr. Castellucci is past president of the Italian Endodontic Society, past president of the International Federation of Endodontic Associations, an active member of the European Society of Endodontology, active member of the American Association of Endodontists, and a visiting professor of endodontics at the University of Florence Dental School. He is editor of *The Italian Journal of Endodontics* and of *The Endodontic Informer*, founder and president of The Warm Gutta Percha Study Club and The Micro-Endodontic Training Center, and he is international editor of *Endo Tribune*. An international lecturer, he is the author of the text *Endodontics*, which is now available in English.



This article is an excerpt from Dr. Arnaldo Castellucci's textbook *Endodontics*, which is divided into three volumes and 35 chapters. Volumes 1 and 2 of this endodontic textbook are now available for the first time in English, completely revised with new chapters and many more color illustrations. Each volume comes complete with its own CD-ROM, which includes the complete text and illustrations in PDF files. To order, contact Il Tridente S.R.L., Viale dei Mille 60, 50131 Firenze, Italy, Tel. +39 055 500 1312, Fax +39 055 500 0232, info@iltridente.it, www.iltridente.it.